

# Multisystemic lymphoplasmacytic inflammation associated with PCV-3 in wasting pigs

Jaume Alomar<sup>1</sup> | Viviane Saporiti<sup>2,3</sup> | Mònica Pérez<sup>2,3</sup> | Diogo Gonçalves<sup>4</sup> |  
Marina Sibila<sup>2,3</sup> | Joaquim Segalés<sup>1,3,5</sup> 

<sup>1</sup> Servei de Diagnòstic de Patologia Veterinària, Departament de Sanitat i Anatomia Animals, Facultat de Veterinària, Universitat Autònoma de Barcelona, Bellaterra, Barcelona 08193, Spain

<sup>2</sup> IRTA, Centre de Recerca en Sanitat Animal (CRESA, IRTA-UAB), Campus de la Universitat Autònoma de Barcelona, Bellaterra, Barcelona 08193, Spain

<sup>3</sup> OIE Collaborating Centre for the Research and Control of Emerging and Re-emerging Swine Diseases in Europe (IRTA-CRESA), Bellaterra, Barcelona, Spain

<sup>4</sup> Raporal, SA, Brejo do Lobo, Montijo 2870-683, Portugal

<sup>5</sup> UAB, Centre de Recerca en Sanitat Animal (CRESA, IRTA-UAB), Campus de la Universitat Autònoma de Barcelona, Bellaterra, Cerdanyola del Vallès 08193, Spain

## Correspondence

Joaquim Segalés, Servei de Diagnòstic de Patologia Veterinària, Facultat de Veterinària, Universitat Autònoma de Barcelona, 08193 Bellaterra, Barcelona, Spain.  
Email: [joaquim.segales@irta.cat](mailto:joaquim.segales@irta.cat)

## Funding information

E-RTA2017-00007-00-00 INIA Project from the Instituto Nacional de Investigación y Tecnología Agraria y Alimentaria (Spanish Government)

## Abstract

Porcine circovirus 3 (PCV-3) has been detected in diseased and healthy pigs of different ages. Several reports have associated the agent with reproductive failure and mummified and stillborn piglets. One report from North America has proposed a consistent potential association with postweaning disorders. Thus, the present case report aimed to describe the histopathological lesions and their association with the presence of PCV-3 genome in postweaning pigs showing growth-retardation and thrown-back ears. All affected animals displayed multi-organic lymphoplasmacytic periarteritis, lymphocytic myocarditis and/or lymphoplasmacytic meningoencephalitis. PCV-3 genetic material was detected by *in situ* hybridization within the lesions and confirmed by PCV-3 real-time quantitative PCR detection in tissues. This study represents the first report of PCV-3 associated with clinical disease in postweaning pigs in Europe.

## KEYWORDS

*in situ* hybridization, myocarditis, periarteritis, pig, porcine circovirus 3, postweaning

## 1 | INTRODUCTION

Porcine circoviruses (PCVs) are circular, non-enveloped, single-stranded DNA viruses included in the family *Circoviridae*, genus *Circovirus* (Biagini et al., 2012). PCVs have worldwide distribution in swine herds and, until few years ago, only two species were known to infect pigs: *Porcine circovirus 1* (PCV-1), which is considered non-pathogenic to pigs, and *Porcine circovirus 2* (PCV-2), which is widely

known as a major pathogen for swine as the cause of porcine circovirus diseases (PCVD) (Segalés, 2012). A third PCV, named *Porcine circovirus 3* (PCV-3), was discovered in 2015 in the United States by means of metagenomics (Palinski et al., 2017; Phan et al., 2016). It is known that PCV-3 is distributed worldwide and has been found in samples from sick and healthy pigs (Klaumann et al., 2018; Saporiti et al., 2020) as well as wild boar (Franzo et al., 2018; Klaumann et al., 2019). Recently, a fourth PCV was found in several Chinese farms (Zhang et al., 2020),

This is an open access article under the terms of the [Creative Commons Attribution-NonCommercial](https://creativecommons.org/licenses/by-nc/4.0/) License, which permits use, distribution and reproduction in any medium, provided the original work is properly cited and is not used for commercial purposes.

© 2021 The Authors. *Transboundary and Emerging Diseases* published by Wiley-VCH GmbH

but not in Italy and Spain (Franzo et al., 2020), which has been named *Porcine circovirus 4* (PCV-4) (Opriessnig et al., 2020). PCV-4 genetic material has been detected in 7- to 12-week-old pigs suffering from porcine dermatitis and nephropathy syndrome, and respiratory and enteric clinical signs, as well as in healthy animals of all age groups (Opriessnig et al., 2020; Zhang et al., 2020).

PCV-2 is a well-established pig pathogen, but very demanding criteria were established to diagnose PCVDs (Grau-Roma et al., 2012). For instance, the diagnosis of PCV-2-systemic disease (PCV-2-SD) needs the assessment of three major criteria, namely clinical signs, histopathological lesions in lymphoid tissues and presence of the virus within these lesions (Segalés, 2012). Disease causality demonstration for a ubiquitous agent is not an easy task, and most of the reports published to date on PCV-3 (Opriessnig et al., 2020) are based on the detection of viral genome in sick animals. However, the mere presence of nucleic acid in a sample does not constitute evidence of disease causality (Arruda et al., 2019). Among all published studies, only few of them showed the presence of PCV-3 within lesions, which may account for this virus as a cause of the observed clinical condition (Arruda et al., 2019; Kim et al., 2018; Phan et al., 2016). Moreover, only one has demonstrated a significant amount of PCV-3 nucleic acid in the damaged tissues of postweaning pigs, further suggesting the role of this virus in causality (Arruda et al., 2019).

To date, there are no peer-reviewed published reports of PCV-3 associated disease in pigs from Europe, although cases with high viral loads in stillborn and lactating piglets from United Kingdom and Spain have been described (Saporiti et al., 2021; Williamson et al., 2019). Here, we report the first case of postweaning disease associated with PCV-3 described in Europe.

## 2 | MATERIALS AND METHODS

Since January 2020, a Portuguese 200 sow-farm with a 3-week farrowing batch production system weaning 30.5 piglets per sow/year suffered from a clinical disorder in nursery piglets (4-10 weeks of age). It consisted of growth-retarded animals showing thrown-back ears (the condition has been vulgarly named as 'aviator' or 'flying pig syndrome'), wasting and rough hair (Figure 1). The initial incidence of the condition was 1.25%, increasing up to 3.85% in April 2020 and decreasing to 0.90% in November of the same year. The overall incidence for year 2020 was 1.41% (range 0.31-3.85%).

By October and November 2020, the Veterinary Pathology Diagnostic Service (SDPV) of the *Universitat Autònoma de Barcelona* received four affected animals and two non-affected ones from the same batch to be used as controls. All animals were subjected to an exhaustive necropsy.

Tissue samples (superficial inguinal and submandibular lymph nodes, Peyer's patches, tonsil, heart, central nervous system [CNS] – cerebrium, cerebellum and pons –, kidneys, lungs, spleen, large and small bowel, liver and/or nasal turbinate) were collected and fixed by immersion in a 10% buffered formaldehyde solution for 48 h. Tissues were subsequently embedded in paraffin wax, sectioned at 3 µm,



**FIGURE 1** Postweaning pig suffering from the so-called 'flying pig syndrome' with wasting and thrown-back ears

and stained with hematoxylin and eosin (HE) for routine histology assessment.

The same fixed tissues were used to assess the presence of PCV-3 genetic material by *in situ* hybridization (ISH) using RNAscope® technology (Saporiti et al., 2021). Additionally, a pool of paraffin-embedded tissues (Table 1) was used for DNA extraction to detect PCV-3 genome by real-time quantitative PCR (qPCR) (Saporiti et al., 2021). For the DNA extraction, four tissue slices were treated firstly with 1 ml of xylol and afterwards with 1 ml of absolute ethanol. Then, the obtained tissue pellet was dried and resuspended according to the instructions of the QiAamp® DNA FFPE Tissue kit.

Since the condition was clinically characterized by growth retardation, two major pathogens able to cause a similar clinical picture were considered (PCV-2 and porcine reproductive and respiratory syndrome virus, PRRSV). Specifically, PCV-2 and PRRSV antigens were investigated by immunohistochemical (IHC) techniques (Rosell et al., 1999; Segalés et al., 2002) on formalin-fixed, paraffin embedded tissues (lung, tonsil and superficial inguinal and submandibular lymph nodes).

## 3 | RESULTS

Macroscopic evaluation of clinically affected pigs showed poor body condition with rough hair but no evidence of gross lesions in internal organs. Non-diseased animals were of smaller size but were clinically healthy and did not show gross lesions as well.

Microscopically, diseased pigs had multi-organic, moderate to severe lymphoplasmacytic periarteritis and arteritis in mesenteric arteries (4/4), heart (4/4), kidneys (4/4), spleen (4/4), portal arterioles (3/4), meninges (2/4), lungs (2/4) and/or stomach (2/4). The histological

**TABLE 1** Real time quantitative PCR results expressed as PCV-3 copies/ml of resuspended formalin-fixed, paraffin-embedded tissues obtained for each studied pig

Ref.	Pool of formalin-fixed, paraffin-embedded tissues	Viral load (copies of PCV-3/ml)
Pig No. 1	Lymph node, lung, tonsil, brain, liver, heart, kidney, nasal turbinate.	$1.20 \times 10^7$
Pig No. 2	Lymph node, lung, tonsil, brain, liver, heart, spleen, kidney, nasal turbinate.	$1.45 \times 10^7$
Pig No. 3	Lymph node, lung, tonsil, brain, liver, heart, spleen, kidney.	$9.38 \times 10^7$
Pig No. 4	Lymph node, lung, tonsil, brain, liver, heart, spleen, kidney.	$4.10 \times 10^7$
Pig No. 5 <sup>a</sup>	Lymph node, lung, tonsil, brain, liver, heart, spleen, kidney, small bowel.	$1.56 \times 10^3$
Pig No. 6 <sup>a</sup>	Lymph node, lung, tonsil, brain liver, heart, spleen, kidney, small bowel.	$1.39 \times 10^3$

<sup>a</sup>Non-diseased pigs.

features of affected arteries were circumferential or segmental lymphoplasmacytic inflammatory infiltration (Figure 2A). These inflammatory infiltrates expanded and disrupted the periarteriol connective tissue and tunica adventitia, only affecting the tunica media and intima in the most severe cases. Smooth muscle cells of the tunica media showed a mild-to-intense vacuolization with loss of cytoplasm borders definition. Occasionally, endothelial cells were plumped to the lumen and leukocytes attached to the endothelium displaying rolling and exocytosis. Besides the blood vessel lesions, the CNS of the four sick pigs had mild lymphoplasmacytic meningoencephalitis (Figure 2B), characterized by diffuse gliosis and multifocal discrete perivascular cuffing. Other observed lesions in diseased animals were generalized lymphoplasmacytic myocarditis (4/4), mild lymphoplasmacytic and histiocytic interstitial pneumonia (1/4), mild lymphoplasmacytic nephritis (Figure 2C) (3/4) and mild lymphoplasmacytic periportal hepatitis (3/4). Nasal turbinates were examined in only two pigs, which displayed mild lymphoplasmacytic rhinitis and mild lymphoplasmacytic periarteritis. Control animals did not show gross or microscopic lesions (Figure 2D).

In all sick animals, the detected PCV-3 nucleic acid by in situ hybridization (ISH) was found in association of the abovementioned lesions. In the evaluated samples of the four sick animals, all arteries with consistent histologic lesions showed a segmental or circumferential PCV-3 labeling of smooth muscle-like cells, lymphocytes, plasma cells and endothelial cells (Figure 2E). Viral genome detection in lymphoid tissues was observed as stellate-shape cells in germinal centers of lymph nodes (2/3), tonsils (2/3), Peyer's patches (1/3) and white pulp of the spleen (3/4). In the heart, widespread PCV-3 labelling was present in myocardiocyte-like cells (4/4) (Figure 2E, inset). CNS showed extensive labelling in spotted and stellate-like cells, mainly in the white matter but also in multiple foci in the grey matter in neuronal body-like cells (4/4) from cerebellum and cerebrum (Figure 2F and inset). Besides arterial labelling, viral RNA was detected multifocally in the cytoplasm of renal tubular epithelial cells (2/4) (Figure 2G) in the lung, type I pneumocyte-like cells and interstitial macrophage-like cells were labeled (2/4). Scant positivity in the Kupffer's cells (3/4), scattered labelling in intestinal smooth muscle-like cells of the small bowel and spiral colon (1/4) and scant positivity in macrophage-like cells in the

nasal turbinate inflammatory infiltrate (2/2) were also observed. Overall, the number of labeled cells were directly proportional to the severity of lesion detected, although in lung and brain the amount of viral genome was high in comparison with the severity of lesions (high viral amount but mild lesions). Control animals had no evidence of PCV-3 genome detection by ISH (Figure 2H).

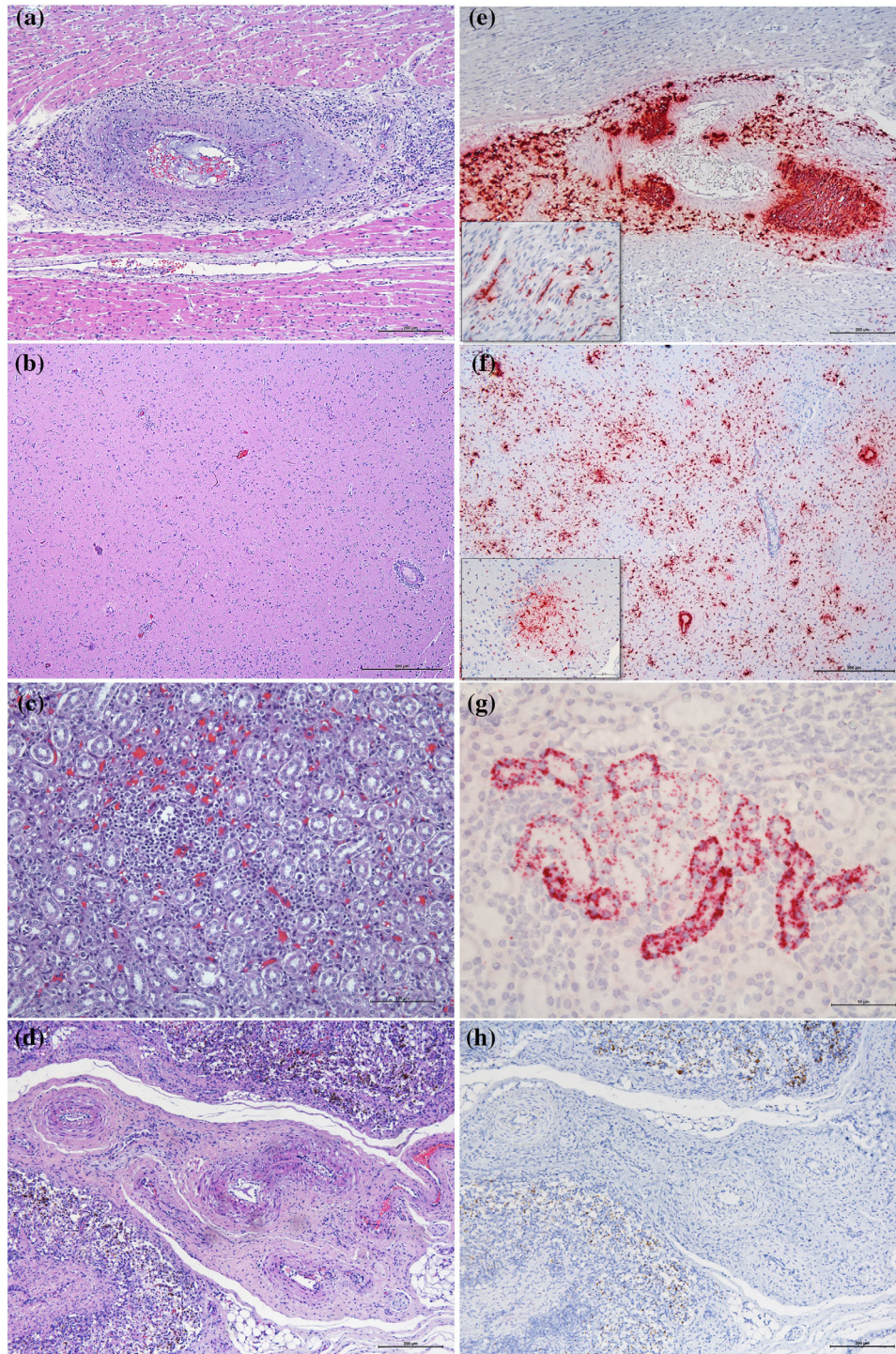
All sick and control pigs were positive for PCV-3 qPCR (Table 1). The four clinically affected animals with histological lesions and ISH labeling had high viral loads in tissues (from  $1.20$  to  $9.38 \times 10^7$  copies/ml of the resuspended pellet from deparaffined tissues). The two control animals had low viral load in the pooled tissues (from  $1.39$  to  $1.56 \times 10^3$  copies/ml of the resuspended pellet from deparaffined tissues).

Furthermore, all animals were evaluated for PCV-2 and PRRSV antigen detection by IHC techniques, yielding negative results by both techniques. Noteworthy, none of the animals suffered from lesions consistently attributable to those viruses.

## 4 | DISCUSSION

The present report described a wasting disease in postweaning pigs showing multisystemic inflammatory lesions associated to PCV-3 infection. To date, most of the descriptions of PCV-3 detection in sick animals have been based on qPCR (Opriessnig et al., 2020), which makes it difficult to establish a sound causality association of the virus with the clinical-pathological condition. Therefore, and considering the widespread nature of PCV-3 over the world, it is urgently needed to establish criteria for a formal case definition of PCV-3 associated disease/s (PCV-3-AD). This aspect is even more important considering that both sick and healthy pigs in a farm may be infected with this virus, as highlighted by the qPCR results in the present study.

A similar situation occurred more than two decades ago with a genetically related circovirus, PCV-2, also ubiquitous. The sole presence of the virus in a pig does not constitute a diagnosis of PCVDs, and the triad (1) clinical signs, (2) moderate to severe histological lesions and (3) moderate to high amount of PCV-2 in damaged tissues, is required to substantiate a definitive diagnosis (Segalés, 2012). Equivalent criteria have been demonstrated in very few reports for



**FIGURE 2** Histology (H&E stain, A, B, C, D) and PCV-3 in situ hybridization (E, F, G, H) results. (A) Heart; intense lymphoplasmacytic periarteritis from pig No. 3. (B) Brain; segmental periarteritis in meningeal artery and cortical section without lesions. (C) Kidney; mild interstitial lymphoplasmacytic nephritis from pig No. 4. (D) Mesenteric arteries; histological normal arteries from control pig, No. 5. (E) Heart; PCV-3 genome detection in arterial wall and endothelial cells from pig No. 3. (Inset) PCV-3 nucleic acid detection in myocardiocyte-like cells of the same animal. (F) High amount of PCV-3 genome in cerebrum white matter and mild-to-moderate in grey matter from pig No. 3. (Inset) PCV-3 labelling in neuron-like cells of the same case. (G) PCV-3 nucleic acid detection in renal tubular epithelial cells of the same animal. (H) Mesenteric arteries; lack of PCV-3 detection by ISH in control pig, No. 5

PCV-3, mainly regarding reproductive failure (Arruda et al., 2019; Palinski et al., 2017; Saporiti et al., 2021; Williamson et al., 2019) and myocarditis and periarteritis in postweaning pigs (Arruda et al., 2019; Phan et al., 2016). Some descriptions have used ISH to detect PCV-3 genome in different tissues from sick animals, but the amount of viral material detected was low (Kim et al., 2018; Phan et al., 2016), which poses uncertainty on the real causality of the condition.

PCV-3 genome was found to high loads by qPCR in the four diseased pigs, coinciding with the high viral nucleic acid amount detected by ISH in damaged tissues. Importantly, PCV-3 DNA was also detected in the non-diseased animals by qPCR, even to a low amount, which coincided with the lack of detection by the ISH. These results further mirror PCV-2 in the sense that overt disease is described when high viral loads are detected within lesions (Segalés, 2012).

Arruda et al. (2019) described myocarditis and multi-organic periarteritis associated with a significant amount of PCV-3 genome in 12 cases of postweaning pigs suffering from different clinical conditions in the United States. However, to the authors' knowledge, no further cases have been reported around the world to date. Therefore, the cases described here represent the first description of PCV-3-AD in postweaning pigs in Europe.

Importantly, an abundant amount of PCV-3 genome was found in all four diseased pigs, including the brain (mainly cerebrum and cerebellum), a fact that has not been previously reported in postweaning pigs (Arruda et al., 2019). However, these animals did not show CNS clinical signs despite the mild meningoencephalitis associated with PCV-3. Interestingly, presence of viral genome in brain has been found in cases of perinatal disease in several reports (Arruda et al., 2019; Saporiti et al., 2021; Williamson et al., 2019).

Obtained data suggest that PCV-3 may replicate in epithelial cells from the endothelia, as well as renal tubular cells, pneumocytes, smooth muscle cells from blood vessels, myocardial cells, dendritic cells/macrophages and glial cells. Some of these cell types have already been suggested as supporting viral replication by means of experimental settings (Mora-Díaz et al., 2020). In any case, much more research is needed to establish the pathogenesis of PCV-3 infection in pigs and to elucidate the cells supporting viral replication.

To date, minimal information does exist regarding the pathogenesis of PCV-3 infection (Mora-Díaz et al., 2020). It could be speculated that this novel virus may require the presence of other infectious and/or non-infectious co-factors to trigger disease, in a similar manner as happen with PCV-2 (Grau-Roma et al., 2012). Therefore, more extensive experimental and field data is necessary to ascertain the importance of PCV-3 as a cause of disease in swine.

Although two important diseases as those caused by PCV-2 and PRRSV were ruled out, the potential causality of the condition by PCV-3 should be further confirmed in a wider set of animals displaying described lesions. PCV-3 nucleic acid was definitively located within the inflammatory lesions, but the concomitance of other pathogens or conditions in triggering the clinical condition cannot be excluded.

In summary, the present report describes the first documented case of postweaning wasting disease showing multisystemic angiocentric inflammatory lesions associated with PCV-3 in pigs in Europe.

## ACKNOWLEDGMENTS

This research was funded by E-RTA2017-00007-00-00 INIA Project from the Instituto Nacional de Investigación y Tecnología Agraria y Alimentaria (Spanish Government) and CERCA Programme/Generalitat de Catalunya. The authors thank the technical support of Blanca Pérez and Aida Neira, from the Servei de Diagnòstic de Patologia Veterinària (SDPV) at the Universitat Autònoma de Barcelona and Eva Huerta from the Institut de Recerca i Tecnologia Agroalimentàries.

## CONFLICT OF INTEREST

The authors declare no conflict of interest.

## DATA AVAILABILITY STATEMENT

Data published in this report are available upon request.

## ORCID

Joaquim Segalés  <https://orcid.org/0000-0002-1539-7261>

## REFERENCES

- Arruda, B., Piñeyro, P., Derscheid, R., Hause, B., Byers, E., Dion, K., Long, D., Sievers, C., Tangen, J., Williams, T., & Schwartz, K. (2019). PCV3-associated disease in the United States swine herd. *Emerging Microbes & Infections*, 8(1), 684–698. <https://doi.org/10.1080/22221751.2019.1613176>
- Biagini, P., Bendinelli, M., Hino, S., Kakkola, L., Mankertz, A., Niel, C., Okamoto, H., Raidal, S., Teo, C. G., & Todd, D. (2012). Circoviridae. In A. M. Q. King, M. J. Adams, E. B. Carstens, E. J. Lefkowitz (Eds.), *Virus taxonomy: classification and nomenclature of viruses. Ninth report of the International Committee on Taxonomy of Viruses* (pp. 343–349). Elsevier Academic Press.
- Franzo, G., Legnardi, M., Hjulager, C. K., Klaumann, F., Larsen, L. E., Segalés, J., & Drigo, M. (2018). Full-genome sequencing of porcine circovirus 3 field strains from Denmark, Italy and Spain demonstrates a high within-Europe genetic heterogeneity. *Transboundary and Emerging Diseases*, 65(3), 602–606. <https://doi.org/10.1111/tbed.12836>
- Franzo, G., Ruiz, A., Grassi, L., Sibila, M., Drigo, M., & Segalés, J. (2020). Lack of Porcine circovirus 4 genome detection in pig samples from Italy and Spain. *Pathogens (Basel, Switzerland)*, 9(6), 433. <https://doi.org/10.3390/pathogens9060433>
- Grau-Roma, L., Baekbo, P., Rose, N., Wallgren, P., Fraile, L., Larsen, L., & Segalés, J. (2012). Clinical and laboratory studies on herds affected with postweaning multisystemic wasting syndrome in Denmark, France, Spain, and Sweden: Disease progression and a proposal for herd case definition. *Journal of Swine Health and Production*, 20, 129–136.
- Kim, S. C., Nazki, S., Kwon, S., Juhng, J. H., Mun, K. H., Jeon, D. Y., Jeong, C. G., Khatun, A., Kang, S. J., & Kim, W. I. (2018). The prevalence and genetic characteristics of porcine circovirus type 2 and 3 in Korea. *BMC Veterinary Research*, 14(1), 294. <https://doi.org/10.1186/s12917-018-1614-x>
- Klaumann, F., Correa-Fiz, F., Franzo, G., Sibila, M., Núñez, J. I., & Segalés, J. (2018). Current Knowledge on Porcine circovirus 3 (PCV-3): A novel virus with a yet unknown impact on the swine industry. *Frontiers in Veterinary Science*, 5, 315. <https://doi.org/10.3389/fvets.2018.00315>
- Klaumann, F., Dias-Alves, A., Cabezón, O., Mentaberre, G., Castillo-Contreras, R., López-Béjar, M., Casas-Díaz, E., Sibila, M., Correa-Fiz, F., & Segalés, J. (2019). Porcine circovirus 3 is highly prevalent in serum and tissues and may persistently infect wild boar (*Sus scrofa scrofa*). *Transboundary and Emerging Diseases*, 66(1), 91–101. <https://doi.org/10.1111/tbed.12988>
- Mora-Díaz, J., Piñeyro, P., Shen, H., Schwartz, K., Vannucci, F., Li, G., Arruda, B., & Giménez-Lirola, L. (2020). Isolation of PCV3 from perinatal and

- reproductive cases of PCV3-associated disease and *in vivo* characterization of PCV3 replication in CD/CD growing pigs. *Viruses*, 12(2), 219. <https://doi.org/10.3390/v12020219>
- Opriessnig, T., Karuppanan, A. K., Castro, A., & Xiao, C. T. (2020). Porcine circoviruses: current status, knowledge gaps and challenges. *Virus Research*, 286, 198044. <https://doi.org/10.1016/j.virusres.2020.198044>
- Palinski, R., Piñeyro, P., Shang, P., Yuan, F., Guo, R., Fang, Y., Byers, E., & Hause, B. M. (2017). A novel porcine circovirus distantly related to known circoviruses is associated with porcine dermatitis and nephropathy syndrome and reproductive failure. *Journal of Virology*, 91(1), e01879-16. <https://doi.org/10.1128/JVI.01879-16>
- Phan, T. G., Giannitti, F., Rossow, S., Marthaler, D., Knutson, T. P., Li, L., Deng, X., Resende, T., Vannucci, F., & Delwart, E. (2016). Detection of a novel circovirus PCV3 in pigs with cardiac and multi-systemic inflammation. *Virology Journal*, 13(1), 184. <https://doi.org/10.1186/s12985-016-0642-z>
- Rosell, C., Segalés, J., Plana-Durán, J., Balasch, M., Rodríguez-Arriola, G. M., Kennedy, S., Allan, G. M., McNeilly, F., Latimer, K. S., & Domingo, M. (1999). Pathological, immunohistochemical, and *in-situ* hybridization studies of natural cases of postweaning multisystemic wasting syndrome (PMWS) in pigs. *Journal of Comparative Pathology*, 120(1), 59–78. <https://doi.org/10.1053/jcpa.1998.0258>
- Saporiti, V., Cruz, T. F., Correa-Fiz, F., Núñez, J. I., Sibila, M., & Segalés, J. (2020). Similar frequency of Porcine circovirus 3 (PCV-3) detection in serum samples of pigs affected by digestive or respiratory disorders and age-matched clinically healthy pigs. *Transboundary and Emerging Diseases*, 67(1), 199–205. <https://doi.org/10.1111/tbed.13341>
- Saporiti, V., Valls, L., Maldonado, J., Perez, M., Correa-Fiz, F., Segalés, J., & Sibila, M. (2021). Porcine circovirus 3 detection in aborted fetuses and stillborn piglets from swine reproductive failure cases. *Viruses*, 13(2), 264. <https://doi.org/10.3390/v13020264>
- Segalés, J. (2012). Porcine circovirus type 2 (PCV2) infections: clinical signs, pathology and laboratory diagnosis. *Virus Research*, 164(1-2), 10–19.
- Segalés, J., Calsamiglia, M., Rosell, C., Soler, M., Maldonado, J., Martín, M., & Domingo, M. (2002). Porcine reproductive and respiratory syndrome virus (PRRSV) infection status in pigs naturally affected with post-weaning multisystemic wasting syndrome (PMWS) in Spain. *Veterinary Microbiology*, 85(1), 23–30. [https://doi.org/10.1016/s0378-1135\(01\)00474-6](https://doi.org/10.1016/s0378-1135(01)00474-6)
- Williamson, S., Wilson, L., Collins, R., Floyd, T., Grierson, S., & Dastjerdi, A. (2019). Multisystemic inflammation in piglets in a herd with congenital tremor and concurrent deformities. 11th European Symposium of Porcine Health Management, Utrecht, The Netherlands.
- Zhang, H. H., Hu, W. Q., Li, J. Y., Liu, T. N., Zhou, J. Y., Opriessnig, T., & Xiao, C. T. (2020). Novel circovirus species identified in farmed pigs designated as Porcine circovirus 4, Hunan province, China. *Transboundary and Emerging Diseases*, 67(3), 1057–1061. <https://doi.org/10.1111/tbed.13446>

**How to cite this article:** Alomar, J., Saporiti, V., Pérez, M., Gonçalves, D., Sibila, M., & Segalés, J. (2021). Multisystemic lymphoplasmacytic inflammation associated with PCV-3 in wasting pigs. *Transboundary and Emerging Diseases*, 1–6. <https://doi.org/10.1111/tbed.14260>